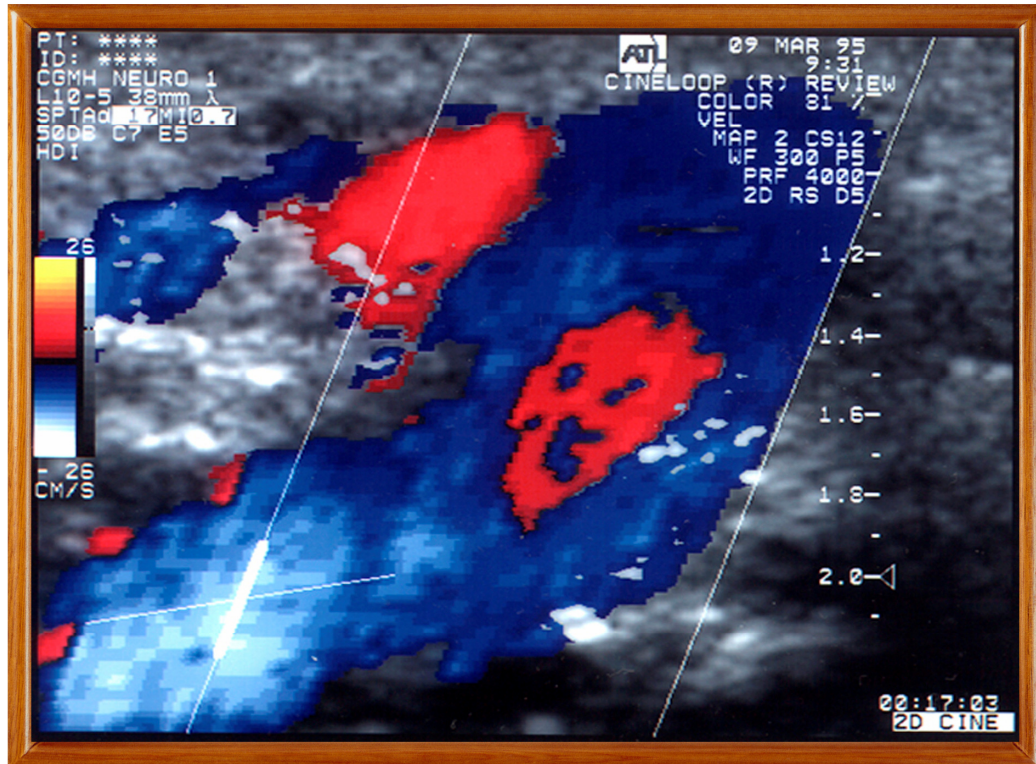
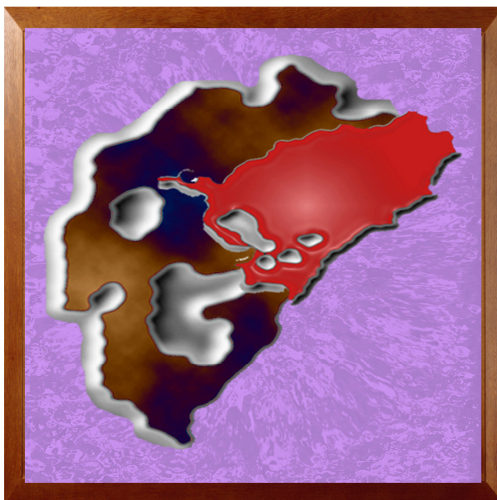

Phantom of the Ultrasound



Physiological disturbed flow in the bifurcation of the common carotid artery resulting in reversed flow that is displayed in red on color Doppler B-mode. Two red color flash were found in this image mimicking the mask in the famous opera *Phantom of the Opera*.



After reconstruction of the red color flash by digital effects, the author named it as:

*Phantom
of the
Ultrasound*

